



RESENTING CLINICAL SIGNS

History: Diagnosed with pericardiocentesis and right-sided CHF yesterday after collapsing and developing abdominal distension. Pericardiocentesis removed 45 ml of hemorrhagic effusion. Currently receiving furosemide, Baytril, Vitamin K, and dexamethasone.

DATE

5/12/22

ECHOCARDIOGRAPHIC FINDINGS

2D, M-mode, and Doppler study.

PERFORMED BY:

Dr. G. Ferrer

INTERPRETED BY

Keith Blass, DVM,
MS, DACVIM
(Cardiology)

Left atrial size is normal. The mitral valve appears normal, though mild mitral regurgitation is present. Left ventricular dimensions are normal. Left ventricular systolic function is normal. The aorta and aortic valve are normal. Right atrial and right ventricular dimensions are normal. The tricuspid valve is normal. The pulmonary artery and pulmonic valve are normal. There is an ~3.13 cm x 2.85 cm homogenous mass in the right atrioventricular (AV) groove. No pericardial effusion is seen.

ECG during echo: Sinus rhythm with periods of an accelerated idioventricular rhythm

PATIENT

Cookie Rodriguez

LA - 35.3 mm
LVIDd - 39.0 mm
LVIDs - 29.0 mm
FS - 25.6%
RA - 26.9 mm
LVOT - 0.77 m/s
RVOT - 0.77 m/s

SPECIES

Canine

ASSESSMENT/RECOMMENDATIONS

BREED

Pitbull

This examination demonstrates a mass located in Cookie's right AV groove, and it's likely that bleeding from the mass was the cause of Cookie's pericardial effusion. While a biopsy would be required to determine the type of mass present, the right AV groove is overrepresented to hemangiosarcoma, which tends to be an aggressive tumor type that commonly metastasizes to the lungs and/or abdominal organs.

SEX

FS

No residual pericardial effusion is seen in today's exam, however, Cookie is at risk for its recurrence at any time, therefore, careful monitoring for the development of clinical signs of cardiac tamponade (ex. weakness, lethargy, collapse, abdominal distension, vomiting, labored breathing) is recommended.

AGE

7 y

Cookie's ECG demonstrates the presence of a sinus rhythm with periods of an accelerated idioventricular rhythm (AIVR). AIVR occurs when a subsidiary pacemaker in the ventricles discharges at a faster than normal rate and "competes" with the sinus node for capture of the heart rhythm. AIVR typically does not cause relevant hemodynamic impairment, however, if its rate increases to the point of becoming ventricular tachycardia (ex. >180 bpm), it could put Cookie at risk for sudden death. If Cookie's AIVR is secondary to her pericardiocentesis procedure, it should be transient, however, it's possible that it could be permanent if secondary to her cardiac mass.

WEIGHT

46 lb

HOSPITAL NAME

Paseos VC

Cookie's ascites should resolve on its own now that she is no longer in cardiac tamponade, however, furosemide may be continued temporarily to expedite this process. No indication for dexamethasone is seen in this exam, and vitamin K would likely only be necessary if a coagulopathy was diagnosed. As for Cookie's AIVR, therapy with sotalol (30 mg BID) would be indicated if her ventricular rate approaches 180 bpm or higher.

REFERRING VET

Dr. Carrasquillo

Thoracic radiographs and an abdominal ultrasound are recommended to evaluate for metastatic



disease. Consultation with an oncologist may be warranted to determine whether chemotherapy and/or radiation therapy could potentially be beneficial treatment options. Consideration can also be given to pericardiectomy as a palliative procedure, as this should prevent additional episodes of cardiac tamponade.

DATE

5/12/22

A recheck ECG is recommended in 1 week. A recheck echocardiogram is recommended in ~3 months, sooner if clinical signs compatible with cardiac tamponade recur.

PERFORMED BY:

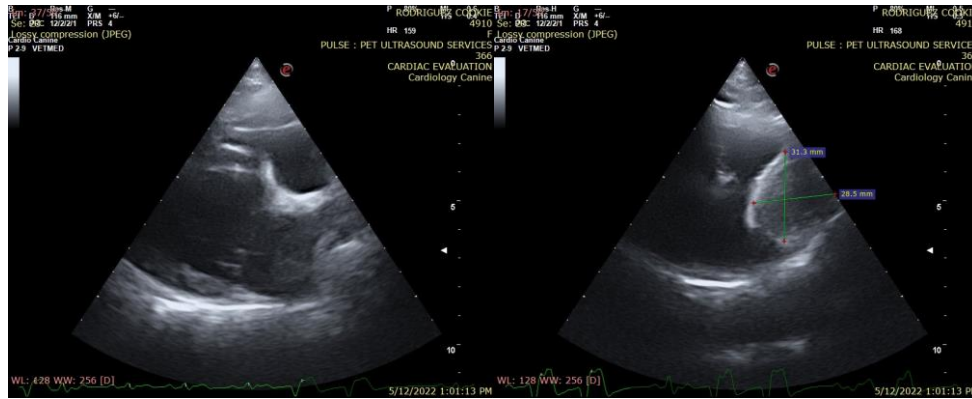
Dr. G. Ferrer

INTERPRETED BY

Keith Blass, DVM,
MS, DACVIM
(Cardiology)

PATIENT

Cookie Rodriguez



SPECIES

Canine

The information and recommendations provided are based on the images presented by the referring veterinarian. No evaluation can be communicated regarding pathology that was not visible in the image/video clips provided.

BREED

Pitbull

Thank you for this referral. If the clinical or image interpretation does not parallel your findings or if I can be of any further assistance please contact me.

SEX

FS

Keith Blass, DVM, MS, DACVIM (Cardiology)
KeithBlass@gmail.com
631-804-5754

AGE

7 y

WEIGHT

46 lb

HOSPITAL NAME

Paseos VC

REFERRING VET

Dr. Carrasquillo